

Does a Longer Delay in Fixation of Talus Fractures Cause Osteonecrosis?

CPT Jaime L. Bellamy, DO,¹ CDR John J. Keeling, MD,² Joseph Wenke, PhD,³
LTC Joseph R. Hsu, MD,³ and the Skeletal Trauma Research Consortium

This retrospective study investigated active duty soldiers with delayed definitive fixation of combat-related talus fractures. The authors predicted a longer delay to internal fixation and a correlation between the timing of fixation and development of osteonecrosis and posttraumatic arthritis. The Joint Theater Trauma Registry was queried by ICD-9 codes for talus fractures. Soldiers, ages 18 to 40, with talus fracture between 2001 and 2008 were included. Radiographs identified the injury type, Hawkins sign, osteonecrosis, and posttraumatic arthritis. Mean time to fixation was 12.9 days. Hawkins sign was observed in 59% of fractures at a mean of 7 weeks. No correlation was found between osteonecrosis or posttraumatic arthritis and open fractures, comminuted fractures, or timing of fixation. Average follow-up was 16 months. This case series has the longest mean time to fixation by more than threefold. There was no correlation of delayed timing of fixation and development of osteonecrosis or posttraumatic arthritis. (Journal of Surgical Orthopaedic Advances 20(1):34–37, 2011)

Key words: delayed fixation, Hawkins sign, osteonecrosis, posttraumatic arthritis, talus fracture

Osteonecrosis (AVN) is the death of bone. In fractures of the talus, it occurs in the neck and body and incidence increases with certain fracture patterns (1). AVN in the talus is recognized on plain radiographs within 6 to 8 months from time of injury and resembles opacity of the involved bone (1, 2). The Hawkins sign is a subchondral radiolucent band also seen at 6 to 8 weeks, indicating that osteonecrosis is unlikely (3). AVN is believed to be caused by a loss of blood supply due to trauma or other medical etiology.

Compromise of the blood supply to the talus is a feared complication resulting from trauma. The main blood supply to the talus is the artery of the tarsal canal (4). Fractures of the talus are due to high-energy trauma in young adults. The incidence of fractures in the talus ranges from 0.1% to 0.85% (1). The possible compromise of blood supply in talus fractures has made the timing of fixation a concerning issue.

Whether or not delayed fixation of talus fractures is the cause of AVN is controversial. There have been

multiple studies regarding the timing of fixation and no correlation has been found linking delayed fixation to formation of AVN. However, emergent fixation has been the current practice because the complications following AVN are potentially devastating. AVN in the talus can lead to painful symptoms, failed fixation, and further surgery (5). Treatment for severe AVN in the talus is initially arthrodesis, followed by talectomy (1). It is unknown whether delayed fixation is the actual cause of AVN.

There are many instances in which fractures sustained in combat undergo delayed fixation because of transport times out of theater. Soldiers are a unique patient population, with a majority representing a more homogeneous population of healthy and active patients. In a study of combat-related injuries sustained during Operation Iraqi Freedom and Operation Enduring Freedom, the Joint Theater Trauma Registry (JTTR) was queried from October 2001 to January 2005 and found to have a total of 454 lower extremity fractures (6). It was predicted that there would be sufficient data with a longer delay to internal fixation than in previous studies in the literature and there would be correlation between the timing of fixation and development of AVN and posttraumatic arthritis.

Methods

This retrospective study investigated a case series of active duty soldiers who underwent delayed open reduction and internal fixation of the talus. After approval from the Institutional Review Board, patients were identified

From ¹Department of Orthopaedics and Rehabilitation, Brooke Army Medical Center, Fort Sam Houston, TX; ²Integrated Department of Orthopaedics and Rehabilitation, National Naval Medical Center, Bethesda, MD; ³United States Army Institute of Surgical Research, Fort Sam Houston, TX. Address correspondence to: Jaime L. Bellamy, DO, Department of Orthopaedics and Rehabilitation, Brooke Army Medical Center, 3851 Roger Brooke Drive, Fort Sam Houston, TX 78234; e-mail: jaime.bellamy@amedd.army.mil.

Received for publication November 10, 2010; accepted for publication November 10, 2010.

For information on prices and availability of reprints call 410-494-4994 X232.
1548-825X/11/2001-0034\$22.00/0

in the JTTR with the use of ICD-9 (International Classification of Diseases, Ninth Revision) diagnostic codes for open and closed talus fractures. Soldiers, ages 18 to 40, with fractures of the talus between January 2001 and November 2008 were included. Patients were traced to the clinical records and those who underwent open reduction and internal fixation and/or treatment at Brooke Army Medical Center were further reviewed. Patients who underwent primary fusion or amputation were excluded.

The radiological evaluation included all of the posttraumatic and postoperative radiographs that were available throughout the course of treatment. Radiographs of the foot and ankle were used to identify the injury type, Hawkins sign, AVN, and posttraumatic arthritis as previously described (7). Talar neck fractures were classified using the Hawkins classification. AVN was defined as an area of increased density of the talus relative to adjacent structures. Delanois et al. described specific zones of AVN as I through IV (8). This was modified and defined as medial by talar zones I and II, lateral by zones III and IV, and complete as zones I to IV. The Hawkins sign was reviewed in radiographs 6 to 8 weeks postinjury to identify revascularization as previously described (3). Posttraumatic arthritis was defined as narrowing of the joint spaces, osteophyte formation, and/or subchondral sclerosis.

Statistical Analysis

The data were analyzed using the SAS 9.1 (Cary, NC). Descriptive statistical analysis for demographic data included mean, median, and standard deviations. Days to fixation and Hawkins sign were compared to AVN and posttraumatic arthritis separately via the Wilcoxon test for nonparametric data and the Student *t*-test for parametric data. Dichotomous variables including injury type and Hawkins sign were compared to AVN and posttraumatic arthritis using the chi-square Fisher exact test. All tests for significance were two-tailed, with level of significance $\alpha = .05$.

Results

Sixteen patients with 17 fractures at Brooke Army Medical Center met inclusion criteria with an average age of 26.5 (range, 21–38). The most frequent mechanism was a floorboard injury due to an improvised explosive device (IED) blast (56%). Other mechanisms of injury included IED blast on foot (31%), motor vehicle accident (6%), and gunshot wound (6%). Ten of 17 fractures were of the talar neck, nine were Hawkins type II, and one was Hawkins type IV. Other fractures included the lateral process, head, and body. Mean time to fixation was

12.9 days, (range, 1–28). Most of the patients underwent fixation at Brooke Army Medical Center, except two. The two exceptions underwent fixation in Afghanistan and Landstuhl Regional Medical Center, within 5 days and 1 day of injury, respectively. The Hawkins sign was present in 59% of fractures, at a mean time of 7 weeks, (range, 4–11). Forty-seven percent (8 of 17 patients) had no complication, with mean fixation time of 14.9 days and 75% had a positive Hawkins sign (Fig. 1).

AVN developed in 7 of 17 fractures, with mean fixation time of 12.5 days; Hawkins sign was present in 20%. Figure 2 shows the talus in a patient who sustained a talar neck fracture with subsequent open reduction and internal fixation and development of AVN. No correlation was found between AVN and open fractures ($p = .45$), comminuted fractures ($p = 1.00$), or timing of fixation ($p = .26$). Of the patients with AVN, the region was most likely complete, and three developed collapse of the talar dome.

Posttraumatic arthritis developed on radiographs of 5 of 17 fractures, with mean fixation time of 13.5 days. No correlation was found between posttraumatic arthritis and open fractures ($p = 1.00$), comminuted fractures ($p = .60$), or timing of fixation ($p = .46$).

Three of 17 fractures developed both AVN and posttraumatic arthritis, with mean fixation time of 9.7 days. No correlation was found between those with both complications ($p = 0.84$) and fracture type or timing of fixation ($p = .77$). No correlation was found between Hawkins sign and osteonecrosis ($p = .35$) or posttraumatic arthritis ($p = .11$). Two of 17 fractures underwent subtalar fusions. Average follow-up was 16 months postoperatively (range, 4–53).

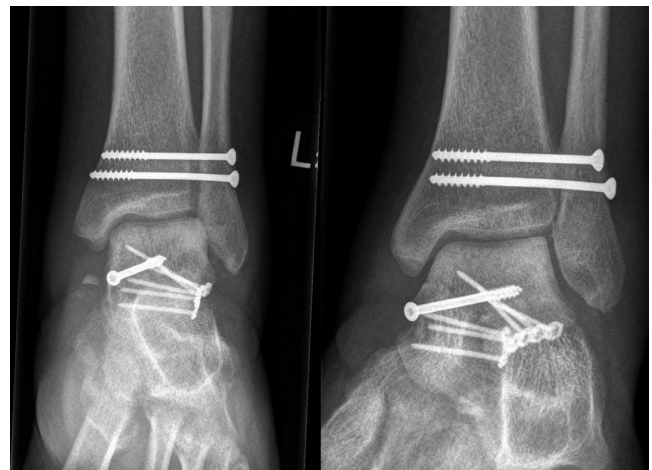


FIGURE 1 Hawkins sign observed as a subchondral radiolucent band in the talar dome 8 weeks postoperatively.

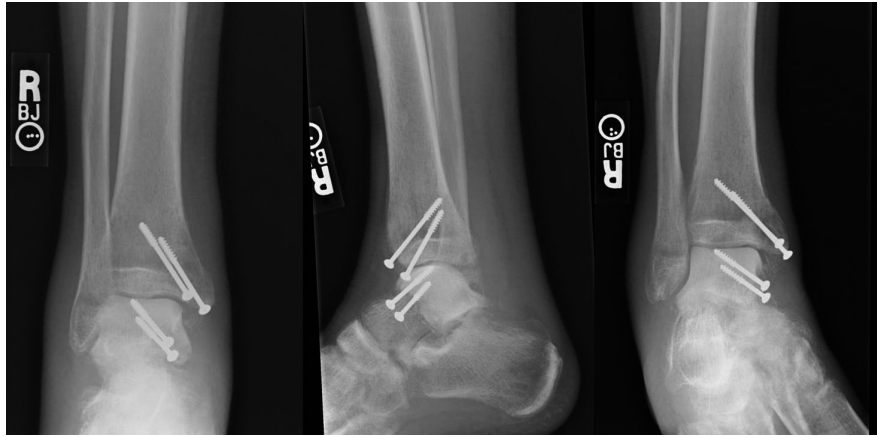


FIGURE 2 AP, lateral, and stress views of the ankle with osteonecrosis of the talus.

Discussion

Because of the infrequency of talar fractures, there is insufficient data in the literature regarding delayed fixation and the outcome of AVN. The classic case series by Hawkins classified talar neck fractures and the development of AVN in 57 patients. In his study, 0% of group I, 42% of group II, and 91% of group III developed AVN (2). He concluded that group I and group III vertical fractures would most likely heal without consequence and form AVN, respectively. However, group II was less predictable. It has been argued that his study most likely overestimated the amount of AVN because the treatment was mostly nonoperative, compared to current studies and practice.

Current practice has shifted to open reduction and internal fixation of displaced talus fractures, creating a question of when is the opportune time of fixation. Studies involving timing of fixation have ranged from hours to days in an effort to reduce complications. A few authors have fixed fractures definitively within 8 and 12 hours, reporting low AVN rates (16% and 16.6%), but rates increased (33% and 32%) with displaced fractures (9–11). Ultimately, the development of AVN was found to be more likely associated with the degree of displacement rather than time to fixation (12), but early fixation was still recommended. The review by Higgins and Baumgaertner found no objective data on surgical timing in fractures of the talus (13). There continues to be insufficient evidence in the literature regarding timing of fixation and development of complications because of the infrequency of talus fractures.

A study of 25 patients found delayed fixation did not affect the prevalence of AVN and posttraumatic arthritis was actually a more common complication following operative treatment (14, 15). Vallier et al. reported that mean time to fixation was less for patients who developed AVN (3.4 days) than for those that did not (5 days),

concluding that there was no correlation between the fixation time and development of AVN in their study of 39 patients (7). Our study had the longest average definitive time to fixation at 12.9 days overall and our results agree with previous studies in which no correlation was found regarding timing of fixation and development of AVN or posttraumatic arthritis.

Even experts in the field are not in agreement on the timing of fixation of talus fractures. Eighty-nine expert orthopaedic trauma surgeons, who were selected as moderators or instructors at major trauma conferences and still operating at level 1 trauma centers, were surveyed. They were asked “what is the maximal acceptable time delay from injury to the operating room representing the minimal standard of care as a level 1 trauma center for a displaced talar neck fracture?” Sixty percent of respondents stated that treatment after 8 hours was acceptable; 46% of respondents stated that treatment at or after 24 hours was acceptable (16). Despite expert opinion and results showing no correlation between timing of fixation and development of AVN, urgent reduction is still recommended for displaced talus fractures (3).

Additionally, Hawkins identified a sign for revascularization of the talus after fracture, indicating fracture healing. At 6 to 8 weeks after injury, the Hawkins sign can be seen as a subchondral radiolucent band of the talar dome on an anteroposterior radiograph. Lindvall et al. questioned the reliability of the Hawkins sign as a prognostic indicator of fracture healing (15). In 2007, Tezval et al. found no Hawkins sign in five patients who developed AVN and positive and partially positive Hawkins sign in 15 patients who did not develop AVN. The Hawkins sign was determined to be a good prognostic indicator of talus fracture healing with 100% sensitivity and 57.7% specificity (3). The Hawkins sign was used in our study; 70% of fractures with a positive Hawkins sign had no complication, supporting the previous studies as a reliable prognostic indicator.

The limitations in this study include that it is a retrospective review; reviewers were not blinded to the patients' clinical or radiographic data; radiographic studies were not on a regular, predetermined timing; the number of patients in the series was small; and the time to follow-up could have had an effect on the results of the study. The incidence of talus fractures is 0.1% to 0.85% of all fractures, with 45% of those being of the talar neck (17). This makes it difficult to collect enough cases for an adequate study size. Our case series involved only 17 patients. Future studies plan to supplement this case series from injuries sustained in the current military conflicts and the addition of multiple military medical centers.

Many military members frequently change duty stations or leave the military entirely and are subsequently lost to follow-up. Our average time to follow-up was 16 months (range, 4–53 months). This is significant because AVN is diagnosed 6 to 8 months after injury on plain radiographs (3). Potentially, those patients who were lost to follow-up before 6 to 8 months may have had AVN that was not visualized on radiographs in this study.

Whether or not delayed fixation of talar fractures is the cause of AVN is controversial. Compared to previous studies, this case series has the longest mean time to fixation by more than threefold. To our knowledge, this is the longest delay reported in the literature. There was no correlation of delayed timing of fixation and development of AVN or posttraumatic arthritis. Due to the small amount of patients, an effort is currently underway to evaluate delayed internal fixation of talus fractures across several military treatment facilities and continued study of our current conflicts.

References

- Fortin, P. T., Balazsy, J. E. Talus fractures: evaluation and treatment. *J. Am. Acad. Orthop. Surg.* 9:114–127, 2001.
- Hawkins, L. G. Fractures of the neck of the talus. *J. Bone Joint Surg. Am.* 52:991–1002, 1970.
- Tezval, M., Dumont, C., Sturmer, K. M. Prognostic reliability of the Hawkins sign in fractures of the talus. *J. Orthop. Trauma* 21(8):538–543, 2007.
- Mulfinger, G. L., Trueta, J. The blood supply of the talus. *J. Bone Joint Surg. Br.* 52(1):160–167, 1970.
- Mindell, E. R., Cisek, E. E., Kartalian, G., Dziob, J. M. Late results of injuries to the talus. Analysis of forty cases. *J. Bone Joint Surg.* 45:221–245, 1962.
- Owens, B. D., Kragh, J. F., Jr., Macaitis, J., et al. Characterization of extremity wounds in Operation Iraqi Freedom and Operation Enduring Freedom. *J. Orthop. Trauma* 21:254–257, 2007.
- Vallier, H. A., Nork, S. E., Barei, D. P., et al. Talar neck fractures: results and outcomes. *J. Bone Joint Surg. Am.* 86(8):1616–1624, 2004.
- Delanois, R. E., Mont, M. A., Yoon, T. R., et al. Atraumatic osteonecrosis of the talus. *J. Bone Joint Surg. Am.* 80(4):529–536, 1998.
- Grob, D., Simpson, L. A., Weber, B. G., et al. Operative treatment of displaced talus fractures. *Clin. Orthop.* 199:88–96, 1985.
- Frawley, P. A., Hart, J. A., Young, D. A. Treatment outcome of major fractures of the talus. *Foot Ankle Int.* 16:339–345, 1995.
- Elgafy, H., Ebraheim, N. A., Tile, M., et al. Fractures of the talus: experience of two level 1 trauma centers. *Foot Ankle Int.* 21:1023–1029, 2000.
- Comfort, T. H., Behrens, F., Gaither, D. W., et al. Long-term results of displaced talar neck fractures. *Clin. Orthop.* 199:81–87, 1985.
- Higgins, T. F., Baumgaertner, M. R. Diagnosis and treatment of fractures of the talus: a comprehensive review of the literature. *Foot Ankle Int.* 20:595–605, 1999.
- Herscovici, D., Anglen, J. O., Archdeacon, M., et al. Avoiding complications in the treatment of pronation-external rotation ankle fractures, syndesmotic injuries, and talar neck fractures. *J. Bone Joint Surg. Am.* 90(4):897–908, 2008.
- Lindvall, E., Haidukewych, G., DiPasquale, T., et al. Open reduction and stable fixation of isolated displaced talar neck and body fractures. *J. Bone Joint Surg. Am.* 86(10):2229–2234, 2004.
- Patel, R., Van Bergeyk, A., Pinney, S. Are displaced talar neck fractures surgical emergencies? A survey of orthopaedic trauma experts. *Foot Ankle Int.* 26(5):378–381, 2005.
- Rammelt, S., Zwipp, H. Talar neck and body fractures. *Injury* 40:120–135, 2009.