

Blast Injuries: Mechanics and Wounding Patterns

CAPT Dana C. Covey, MD,¹ and Christopher T. Born, MD²

Blast and fragment injuries are the most frequently encountered wounds in modern warfare. Explosive devices have become the preferred weapon of domestic and foreign terrorists because they are relatively inexpensive to manufacture and can cause substantial casualties. Although blast injuries have traditionally been associated with the battlefield, this type of trauma is being seen more commonly today among noncombatants due to increasing worldwide terrorism. (Journal of Surgical Orthopaedic Advances 19(1):8–12, 2010)

Key words: blast injuries, musculoskeletal, war wounds

Injuries due to explosive munitions are most commonly encountered on the battlefield; however, blast-related injuries have become the primary disasters to which both civilian and military medical personnel routinely respond (1). Explosive devices are the preferred weapons of today's terrorists, likely because they are inexpensive and readily designed, assembled, transported, and detonated. Recent studies suggest that as of the close of 2005, bomb blasts accounted for 82% of all injuries caused by terrorists worldwide and that this statistic is continuing to trend upward (2–4). In addition, explosions of overwhelming proportions occur outside the military and political environment (5–7).

Pathomechanics and Pathophysiology

Blast Physics

Detonation is the rapid chemical decomposition of an explosive into a gas (8). When an explosion occurs, space formerly occupied by the explosive material is filled with gas under high pressure and temperature, which expands

radially outward as a blast wave moving at supersonic speed. Air is highly compressed on its leading edge (“overpressure”) creating a shock front. The body of the wave, including the associated mass outward movement of air (“blast wind”), follows this front. The blast wind, which travels slower than the blast wave, can propel objects — and human beings — considerable distances and may be as damaging as the original explosion (9, 10). In an open area, the overpressure that results from the blast generally follows a well-defined pressure/time curve, called a “Friedlander wave,” with an initial near-instantaneous spike in the ambient air pressure (Fig. 1) (11). This quickly decays and is followed by a negative pressure wave that sucks debris into the area. The pressure/time curves can vary depending on the local topography, presence of walls or other solid objects, and whether the blast is detonated indoors or outside. The blast wave can reflect off, and flow around, solid surfaces. Reflected waves can be magnified eight to nine times and cause substantially greater injury (12, 13). Blasts that occur in buildings and other confined spaces can be more lethal because of the increased energy of the complex and reflected waves (14, 15). The medium through which the blast wave moves is also a factor in blast intensity. Owing to its increased density, water allows for faster propagation and a longer duration of positive pressure, accounting for the increased severity in that environment. The distance from the explosion's epicenter also factors in, with pressure-wave decay occurring roughly as the inverse cube of the distance (12, 16).

The velocity, duration, and magnitude of the overpressure from the blast wave are dependent on several issues, including the physical size and the type of explosive in the charge being detonated. Explosives can be categorized as either high or ordinary (17). In high explosives, the chemical reaction is triggered by a mechanical shock wave that travels at a high speed causing the explosive to detonate rapidly (8). High explosives further possess

From ¹Department of Orthopaedic Surgery, Naval Medical Center San Diego, San Diego, CA and the Department of Surgery, Uniformed Services University of the Health Sciences, Bethesda; ²Department of Orthopaedic Surgery, Brown University, Providence, RI. Address correspondence to: CAPT Dana C. Covey, MD, MC, USN, Chairman, Department of Orthopaedic Surgery, Naval Medical Center San Diego, San Diego, CA 92134; dana.covey@med.navy.mil.

The views expressed in this article are those of the authors and do not reflect the official policy or position of the Department of the Navy, the Department of Defense, or the United States Government.

Received for publication October 14, 2009; accepted for publication October 20, 2009.

For information on prices and availability of reprints call 410-494-4994 X226.

1548-825X/10/1901-0008\$22.00/0

Copyright © 2010 by the Southern Orthopaedic Association

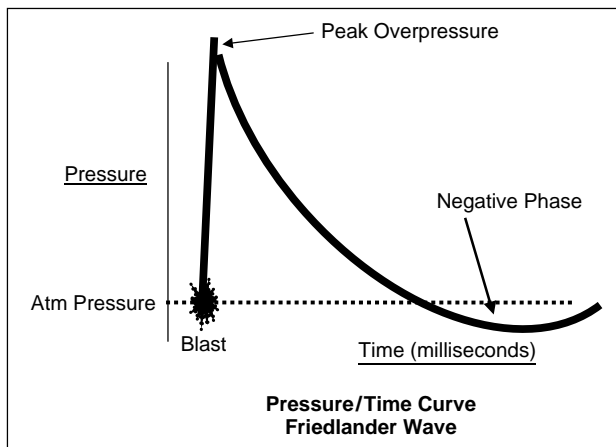


FIGURE 1 Friedlander wave showing the pressure–time relationship of a bomb blast. Note the rapid peak in pressure and then the decline to a negative pressure wave. (Reproduced, with permission, from Covey, D. C., Aaron, R. K., Born, C. T., et al., Instr. Course Lect. 57:65–86, 2008).

a shattering power, termed “brisance.” In contrast, ordinary explosives, such as gunpowder, release energy more slowly by deflagration, a process involving rapid chemical burning.

Blast Injury Categories and Effects on Nonmusculoskeletal Systems

Blast injuries are generally categorized as primary, secondary, tertiary, quaternary, or miscellaneous (Fig. 2) (8, 14).

Primary Blast Injury

A primary blast injury occurs as the shock front and the overpressure blast wave move through the body.

Differences in densities of the body’s anatomic components (particularly at air/fluid interfaces) are susceptible to spalling (the forcible, explosive movement of fluid from more dense to less dense tissues, such as in the human lung) and implosion (when areas of gas are rapidly compressed at the time of shock-front impact and then rapidly re-expand after it passes, causing tissue injury). The latter frequently occurs in the ear/tympanic membrane and intestine. Acceleration/deceleration forces can cause tearing of organ pedicles and mesentery when there is an inertial difference between organ structures. Also, pressure differentials (wherein there is a liquid/gas interface and incompressible, water-filled organs, such as vessels, have fluid forced into the less compressible adjacent structure) can also cause internal injury.

The most susceptible organs to primary blast injury are ears, lungs, and gastrointestinal tract. The ear is the most sensitive, and tympanic membrane rupture can be used as a marker of overpressure exposure. The lungs are moderately more resistant; however, with enough energy exposure, disruption of the capillary–alveolar interface can lead to parenchymal hemorrhage and destruction of the alveolar walls. Emphysematous spaces, as well as pneumothorax, can be created. The interstitial changes of blast lung can lead to acute respiratory distress syndrome. Infiltrates can be seen on a chest radiograph within 90 minutes of the blast (18). In rare instances, air embolism of the vascular tree is believed to lead to sudden death (19, 20). As a gas-filled organ, the gastrointestinal tract can be injured by implosion and ruptured. The mucosal wall can become bruised. Shearing injuries can occur due to acceleration/deceleration relative to more solid, adjacent structures. Other organ systems have varying degrees of response to injury from primary blast, and models have been developed to better study the overall patho-physiologic effects (12, 21–23). The lungs tend to be the

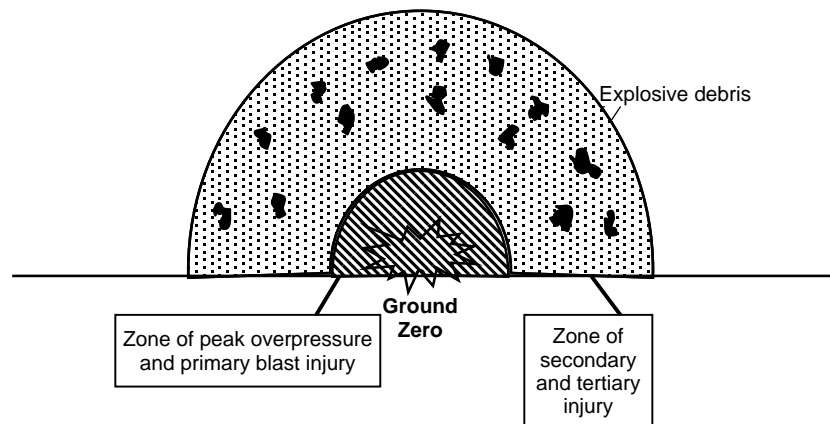


FIGURE 2 Schematic of blast injury zones. With an explosive blast, the area of overpressure rapidly expands but decays in strength. Primary blast injury occurs in close proximity to ground zero, whereas secondary and tertiary injury can extend very far beyond the point of detonation. (Reproduced, with permission, from Covey, D. C., Aaron, R. K., Born, C. T., et al., Instr. Course Lect. 57:65–86, 2008).

predominant nonauditory system injured in most air blasts, whereas the gastrointestinal tract is more susceptible to underwater blasts. Markers are being sought to better diagnose and treat blast overpressure injury (13, 24).

Secondary Blast Injury

Secondary blast injuries occur from objects that have been energized by the explosion to become projectiles. These projectiles, which can be intentionally imbedded into the explosive device to cause wounding, may be a part of the bomb's housing ("primary fragmentation"), or they may be local material, such as rocks or glass, that became airborne due to their proximity to the explosion ("secondary fragmentation"). Most penetrating injuries caused by blast-driven projectiles should be considered as contaminated. Instances of the wounding of victims by bone fragments from the bodies of suicide terrorists or other blast victims have been reported; these injuries require special management (25, 26).

Tertiary and Quaternary Blast Injuries

Tertiary blast injury occurs when a victim is thrown against the ground or an object. Quaternary injury is the result of structural collapse or burns secondary to the detonation. Crush, traumatic amputation, compartment syndrome injuries, and other blunt and penetrating injuries can be common sequelae of structural collapse. Flash burns to exposed skin can occur as a result of the thermal component of the detonation. Secondary fires can cause additional burns and injury from smoke inhalation.

Mechanisms and Patterns of Orthopaedic Injury

Orthopaedic trauma resulting from an explosive detonation is manifested as a primary, secondary, tertiary, or quaternary (miscellaneous) blast injury in isolation or in combination. Although uncommon in survivors, the direct effects of changes in atmospheric pressure caused by the blast wave (primary blast injury) can fracture bones and is probably responsible for limb avulsions in victims exposed to stress waves of sufficiently high intensity (25, 26). Limb amputation can carry a grave prognosis: according to a report by Mellor in 1989, only nine of 52 servicemen who had sustained traumatic amputations from explosions survived (27). Hull analyzed the nature of 41 traumatic amputations in 29 servicemen who survived to reach medical care after sustaining blast injuries and found that for the lower limb, traumatic amputation was significantly higher ($p < .001$) at the level of the tibial tuberosity compared with other sites; for the upper limb, there was a tendency, although not statistically significant, for the traumatic amputation to occur through its distal part (28). Hull and Cooper (29) analyzed the pattern and

mechanism of traumatic limb amputation by an explosive blast by surveying 100 consecutive bomb blast fatalities, 34 of which involved one or more major traumatic amputations. They performed computer modeling with finite-element analysis and then conducted explosive trials using goat hind limb bones. Out of 73 upper and lower limb amputations in their study, only one occurred through a joint (the knee). They postulated that major limb amputation by an explosive blast is a combination of blast wave-induced fracture, followed by limb avulsion through the fracture site by dynamic forces (the blast wind) that cause flailing of the extremity.

Secondary blast injuries caused by flying casing fragments or other objects is the category that most often involves the musculoskeletal system (30), and sufficiently large fragments can rarely cause direct limb amputation (29). Although conventional military explosives may create fragments with initial velocities of up to 1800 m/s (31), it has been proposed that most service members who survived to reach surgical facilities would have been struck by fragments with a velocity below 600 m/s (32). The aerodynamic drag on irregularly shaped fragments also results in rapid deceleration outward from the point of detonation (33, 34). Therefore, depending upon the distance from the blast, fragments that strike the body can vary from high to low velocity, without the streamlining seen in bullets fired through a rifled barrel.

In addition to their lack of streamlining, low-velocity fragments from explosive munitions behave differently than low-velocity bullets in other ways. Upon striking tissue, even at low velocity, these fragments may exhibit a tumbling, or so-called shimmy, effect that can increase the amount of tissue damage (35, 36). Blast fragments often carry environmental debris into the wound and can demonstrate more severe tissue injury than low-velocity bullets (31, 37–39). Furthermore, a large, slow projectile can crush a large amount of tissue, and missile fragmentation that may occur within the body can greatly increase temporary cavity effects (40). One factor or a combination of the above most likely account for the qualitative differences in tissue damage often seen with explosive fragments compared to damage caused by low-velocity gunshot wounds (41). Modern body armor that gives some protection to the thorax and abdomen from secondary blast injury has probably contributed to a greater relative increase in extremity fragment wounds (42).

The blast wind can accelerate bodies in its path and cause tertiary blast injuries of varying severity at a lesser distance from the point of detonation than that reached by secondary missiles (9, 34). Often, victims tumble along the ground sustaining multiple injuries or may be hurled through the air to strike objects or be impaled upon them (34). Fractures, crush injuries, amputations,

and severe soft tissue lacerations and contusions are all possible (43).

Miscellaneous orthopaedic blast injuries are much less common than secondary blast injuries and may include burns from the thermal effects of explosions or from secondary fires (33).

Conclusion

Blast effects from the detonation of explosive ordnance are the most prevalent wounding agents causing military casualties during combat. These injuries are also seen with increasing frequency in the civilian setting as a result of an upsurge in terrorist bombings. In warfare, the limbs are the anatomical regions most commonly injured by explosive munitions, and, as a result of the increasing use of modern body armor, the preponderance of extremity injuries has increased relative to the incidence of thoracoabdominal wounds.

References

1. Frykberg, E. R. Medical management of disasters and mass casualties from terrorist bombings: how can we cope? *J. Trauma* 53:201–212, 2002.
2. Rand. Infrastructure, Safety, and Environment website. RAND MIPT Terrorism Incident Database Project. Available at: <http://www.rand.org/ise/projects/terrorismdatabase>. Accessed March 12, 2007.
3. Kluger, Y. Bomb explosions in acts of terrorism: detonation, wound ballistics, triage and medical concerns. *Isr. Med. Assoc. J.* 5:235–240, 2003.
4. Mallonee, S., Shariat, S., Stennies, G., et al. Physical injuries and fatalities resulting from the Oklahoma City bombing. *JAMA* 276:382–387, 1996.
5. The CBC website. The Halifax Explosion. Available at: <http://www.cbc.ca/halifaxexplosion>. Accessed June 15, 2005.
6. National Archives of Canada website. Tragedy on the home front: Halifax explosion — 6 December, 1917. Available at: http://www.collectionscanada.ca/education/firstworldwar/05180202/0518020203_e.html. National Archives of Canada, RG 24, series D-1-a, vol. 5634, file 37-25-1, part 1. Accessed July 11, 2007.
7. Howell, P. The Explosion website: Available at: <http://www.chron.com/content/chronicle/metropolitan/txcity/index.html>.
8. Stapczynski, S. Blast injuries. *Ann. Emerg. Med.* 11:687–694, 1982.
9. Mellor, S. G. The relationship of blast loading to death and injury from explosion. *World J. Surg.* 16:893–898, 1992.
10. Mellor, S. G. The pathogenesis of blast injury and its management. *Br. J. Hosp. Med.* 39:536–539, 1988.
11. Stuhmiller, J. H., Phillips, Y., Richmond, D. The physics and mechanisms of primary blast injury. In *Textbook of Military Medicine: Conventional Warfare: Ballistic, Blast and Burn Injuries*, pp. 241–270, edited by R. Bellamy, R. Zajtchuk, U.S. Government Printing Office, Washington, DC, 1991.
12. Hull, J. B. Blast. Injury patterns and their recording. *J. Audiovis. Media Med.* 15:121–127, 1992.
13. Mayorga, M. A. The pathology of primary blast overpressure injury. *Toxicology* 121:17–28, 1997.
14. Leibovici, D., Gofrit, O. N., Stein, M., et al. Blast injuries: bus versus open-air bombings: a comparative study of injuries in survivors of open-air versus confined-space explosions. *J. Trauma* 41:1030–1035, 1996.
15. Katz, E., Ofek, B., Adler, J., et al. Primary blast injury after a bomb explosion in a civilian bus. *Ann. Surg.* 209:484–488, 1988.
16. Gans, L., Kennedy, T. Management of unique clinical entities in disaster medicine. *Emerg. Med. Clin. North Am.* 14:301–326, 1996.
17. Shuker, S. T. Maxillofacial blast injuries. *J. Craniomaxillofac. Surg.* 23:91–98, 1995.
18. Caseby, N. G., Porter, M. F. Blast injuries to the lungs: clinical presentation, management and course. *Injury* 8:1–12, 1976.
19. Maynard, R. L., Cooper, G. J., Scott, R. Mechanism of injury in bomb blasts and explosions. In *Trauma-Pathogenesis and Treatment*, pp. 30–41, edited by S. Westby, Heinemann, London, 1988.
20. Coppel, D. L. Blast injury of the lungs. *Br. J. Surg.* 63:735–737, 1976.
21. Jönsson, A., Arvebo, E., Schantz, B. Intrathoracic pressure variations in an anthropomorphic dummy exposed to air blast, blunt impact, and missiles. *J. Trauma* 28(suppl. 1):S135–S131, 1988.
22. Irwin, R. J., Lerner, M. R., Bealer, J. F., et al. Cardiopulmonary physiology of primary blast injury. *J. Trauma* 43:650–655, 1997.
23. Stuhmiller, J. H. Biological response to blast overpressure: a summary of modeling. *Toxicology* 121:91–103, 1997.
24. Harmon, J. W., Sampson, J. A., Graeber, G. M., et al. Readily available serum markers fail to aid in diagnosis of blast injury. *J. Trauma* 28:S153–S159, 1998.
25. Frykberg, E. R., Tepas, J. J. Terrorist bombings: lessons learned from Belfast to Beirut. *Ann. Surg.* 208:569–576, 1988.
26. Guy, R. J., Glover, M. A., Cripps, N. P. J. Primary blast injury: pathophysiology and implications for treatment. Part III: injury to the central nervous system and limbs. *J. R. Nav. Med. Serv.* 86:27–31, 2000.
27. Mellor, S. G., Cooper, G. J. Analysis of 828 servicemen killed or injured by explosion in Northern Ireland 1970–84: the hostile action casualty system. *Br. J. Surg.* 76:1006–1010, 1989.
28. Hull, J. B. Traumatic amputation by explosive blast: pattern of injury in survivors. *Br. J. Surg.* 79:1303–1306, 1992.
29. Hull, J. B., Cooper, G. J. Pattern and mechanism of traumatic amputation by explosive blast. *J. Trauma* 40:S198–205, 1996.
30. Korzinek, K. War injuries of the extremities. *Unfallchirurg.* 96:242–247, 1993.
31. Bowen, T. E., Bellamy, R. F. (eds.). *Emergency War Surgery*, p. 32, United States Department of Defense, Washington, DC, 1988.
32. Bowyer, G. W., Cooper, G. J., Rice, P. Small fragment wounds: biophysics and pathophysiology. *J. Trauma* 40:159S–164S, 1996.
33. Bowyer, G. W., Cooper, G. J., Rice, P. Management of small fragment wounds in war: current research. *Ann. R. Coll. Surg. Engl.* 77:131–134, 1995.
34. Wightman, J. M., Gladish, S. L. Explosions and blast injuries. *Ann. Emerg. Med.* 37:664–678, 2001.
35. Fasol, R., Irvine, S., Zilla, P. Vascular injuries caused by anti-personnel mines. *J. Cardiovasc Surg.* 30:467–472, 1989.
36. Amato, J. J., Billy, L. J., Gruber, R. P., et al. Vascular injuries. An experimental study of high and low velocity missile wounds. *Arch. Surg.* 101:167–174, 1970.
37. Ryan, J. M., Cooper, G. J., Haywood, I. R., et al. Field surgery on a future conventional battlefield: strategy and wound management. *Ann. R. Coll. Surg. Engl.* 73:13–20, 1991.
38. Coupland, R. M. Technical aspects of war wound excision. *Br. J. Surg.* 76:663–667, 1989.

39. Hartl, W., Klammer, H. Gunshot and blast injuries to the extremities. *Acta Chir. Scand.* 154:495–499, 1988.
40. Fackler, M. L. Wound ballistics. A review of common misconceptions. *JAMA* 259:2730–2736, 1988.
41. Covey, D. C. Blast and fragment injuries of the musculoskeletal system. *J. Bone Joint Surg.* 84-A:1221–1234, 2002.
42. Covey, D. C. From the frontlines to the homefront. The crucial role of military orthopaedic surgeons. *J. Bone Joint Surg.* 91-A:998–1006, 2009.
43. Cernak, I., Savic, J., Ignjatovic, D., et al. Blast injury from explosive munitions. *J. Trauma* 47:96–103, 1999.